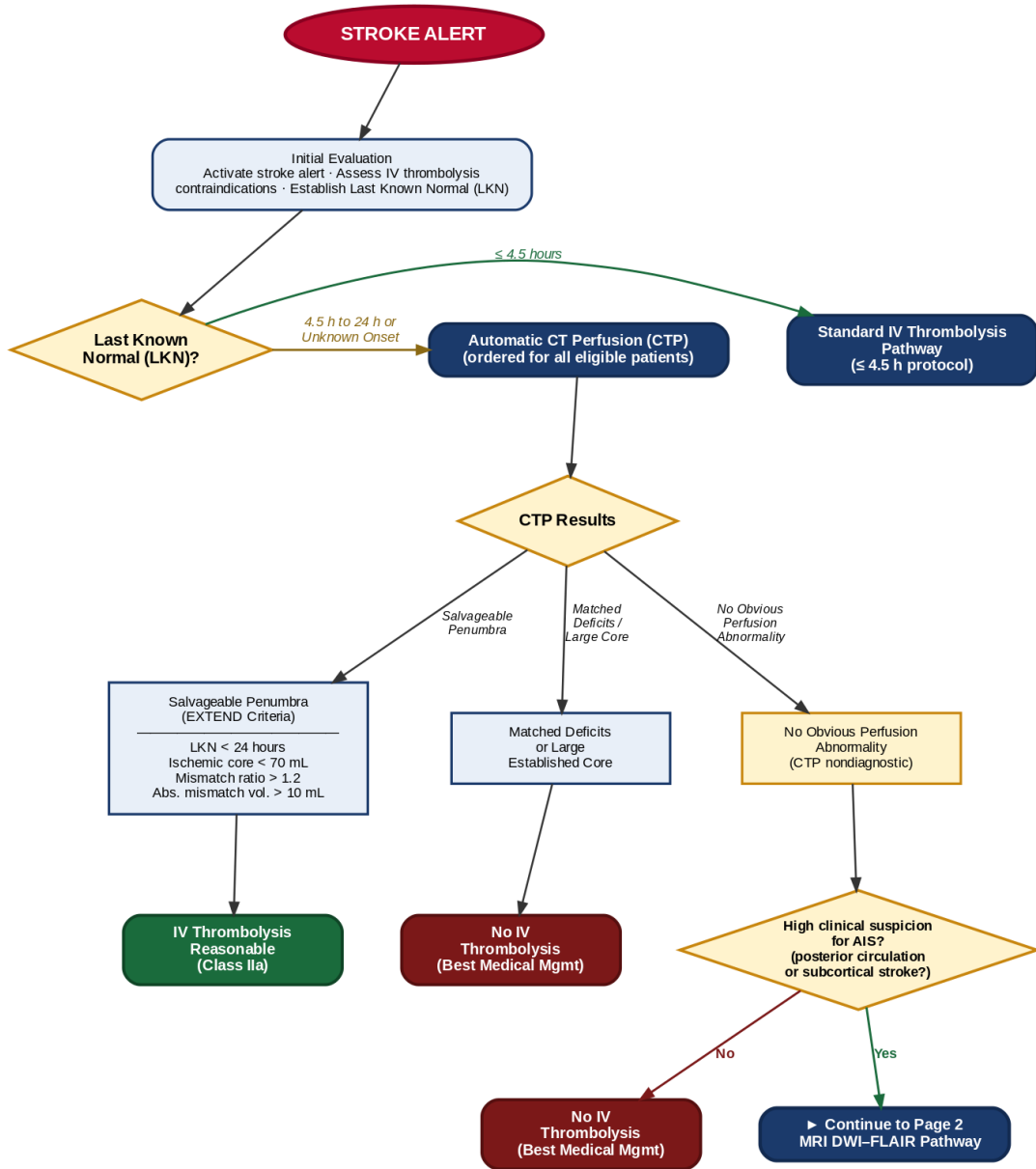
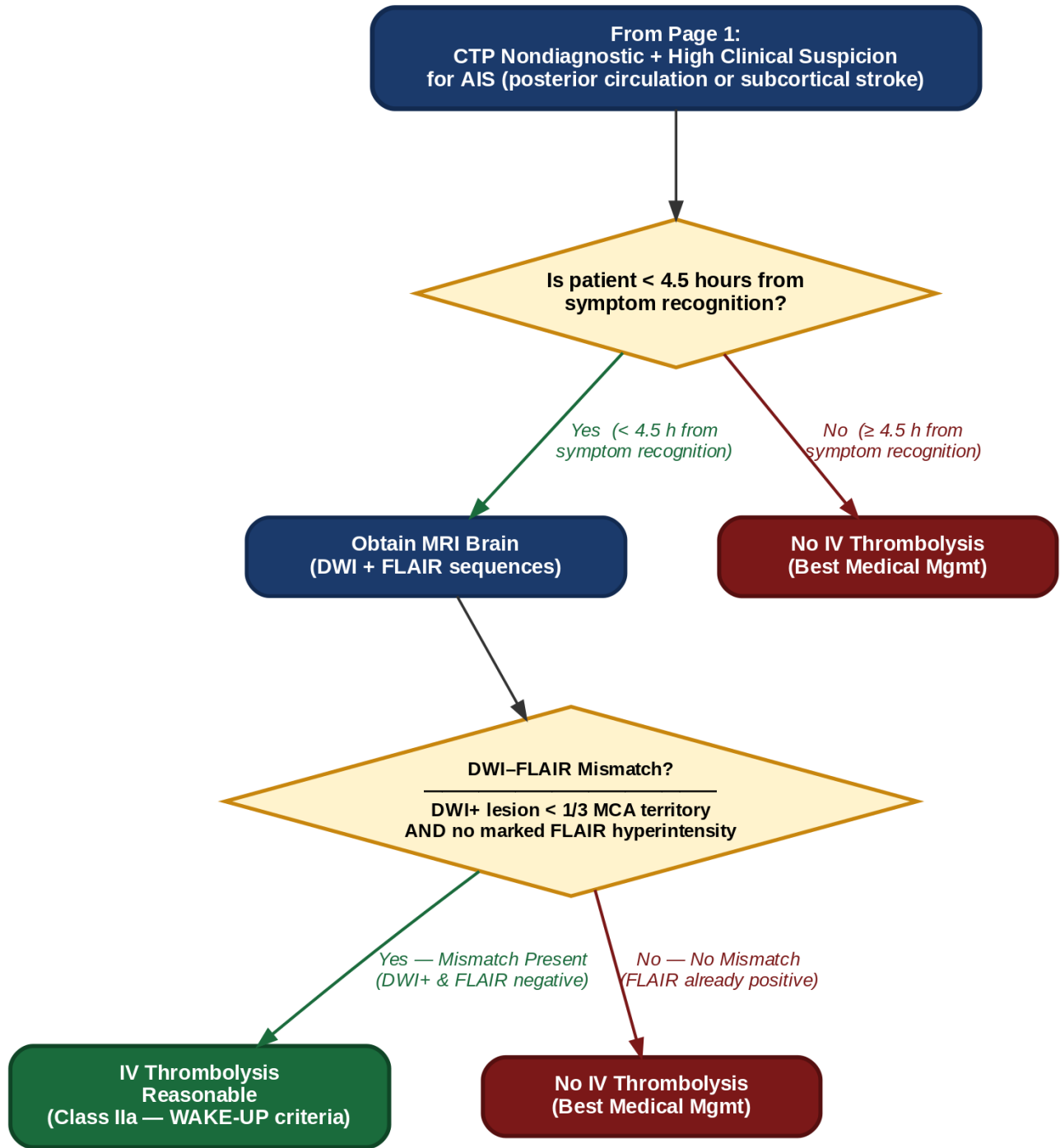


⚠️ DISCLAIMER: Patients with large vessel occlusion (LVO) planning emergent endovascular thrombectomy (EVT) are NOT eligible for IV thrombolysis in the extended 4.5–24h window.

△ **DISCLAIMER:** Patients with large vessel occlusion (LVO) planning emergent endovascular thrombectomy (EVT) are NOT eligible for IV thrombolysis in the extended 4.5–24h window.



Evidence basis: EXTEND Trial (Ma et al., NEJM 2019) — perfusion-selected IVT 4.5–9 h | OPTIONS Trial | HOPE Trial | 2026 AHA/ASA Management of AIS Guidelines



△ Absolute Time Limit: MRI DWI-FLAIR pathway is NOT applicable if patient is > 4.5 hours from symptom recognition. Do NOT use MRI to override matched CTP deficits or large cores.

Evidence basis: WAKE-UP Trial (Thomalla et al., NEJM 2018) — MRI DWI–FLAIR mismatch, unknown-onset stroke | 2026 AHA/ASA Guidelines (Class IIa). Key guardrail: This MRI pathway is selective, not routine — it does NOT override matched CTP deficits, large cores, or presentation > 4.5 h from symptom recognition.